

# Hemoperitoneum from adenomyoma in unscarred non-gravid uterus

## To the editor,

Adenomyosis is characterized by the presence of endometrial gland and stroma in the uterine musculature. It is reported to affect 25-60% of reproductive age women (1). Affected women usually present with dysmenorrhea, heavy menstrual bleeding or chronic pelvic pain. Internal bleeding, hemorrhage and hemoperitoneum due to adenomyosis in non-gravid uterus are all extremely rare and can be easily overlooked in an emergency situation. Furthermore, delay in diagnosis can increase the risk of morbidity and mortality. Hence, acute abdomen in the context of hemoperitoneum in reproductive age women requires a prompt diagnosis.

We report a case of a 34-year old woman who presented with complaints of lower abdominal pain, along with bleeding per vaginum for two days. Over the next several hours, she experienced repeated episodes of pain of variable intensity. Past medical history was unremarkable except for receiving treatment for pelvic inflammatory disease (PID) and ovulation induction drugs in the past. She denied any previous abdominal surgeries.

On examination, she was clinically unstable (temperature normal, moderate pallor, blood pressure 94/56 mmHg and heart rate 104 beats per minute). Abdominal examination revealed tenderness over the right iliac fossa with guarding. On pelvic examination, forniceal fullness was noted bilaterally with slight vaginal bleeding.

Urinary pregnancy test came back negative. Laboratory results showed low hemoglobin at 8.7g/dL, undetectable beta-Human chorionic gonadotropins ( $\beta$ -hCG) at <2 mIU/mL and normal coagulation profile. Abdominal ultrasound revealed a bulky uterus with 4x3.2 cm isoechoic structure with a cavity adjacent to the right coronal region suggestive of rudimentary horn, and bilateral ovaries adherent to the postero-lateral wall of uterus. A massive amount of free fluid was noted in the pelvic

cavity containing a few echogenic foci, suggestive of internal bleeding. So, under the impression of hemoperitoneum of uncertain origin, we proceeded to undertake a diagnostic laparoscopy.

On laparoscopy, the uterus and the bilateral tubo-ovarian complex were firmly adhered to lower anterior abdominal wall. An organized mass of size 7x5 cm was noted attached to the fundus of the uterus and blood was seen trickling from the mass (Figure 1A). The mass was excised and sent for histopathological examination. Hemoperitoneum of about 1,500 mL was evacuated and adhesiolysis was performed to restore the anatomy.

The patient's postoperative period was uneventful and she was discharged on the second postoperative day. Histopathological examination of the excised mass reported adenomyoma (endometrial glands embedded in myometrium) (Figure 1B).

Hemoperitoneum in the context of acute abdomen necessitates prompt action. Common aetiologies are ruptured ectopic pregnancy, corpus luteal cyst, ovarian cyst, vascular rupture and hepatic or splenic rupture (2). Adenomyoma rarely present with hemoperitoneum, especially in non-gravid uterus, and only a few cases have been reported in the literature (1,3). Although the exact cause of vessel rupture remains unclear, venous congestion along with the increased friability of vessels associated with chronic PID or endometriosis have been proposed as the predisposing factors (4). Sudden increase in venous pressure due to uterine contraction or increased intra-abdominal pressure may trigger the rupture of these friable vessel (5). In the present case, we assume that PID (evident from the presence of intra-pelvic dense adhesions and past history of PID) in conjunction with the adenomyosis may have contributed to the rupture of vessels. Preoperative diagnosis was difficult, given the rarity of the entity. Ultrasound remains the first imaging modality for evaluation, though in this case the ultrasonographic diagnosis was unexplained hemoperitoneum.

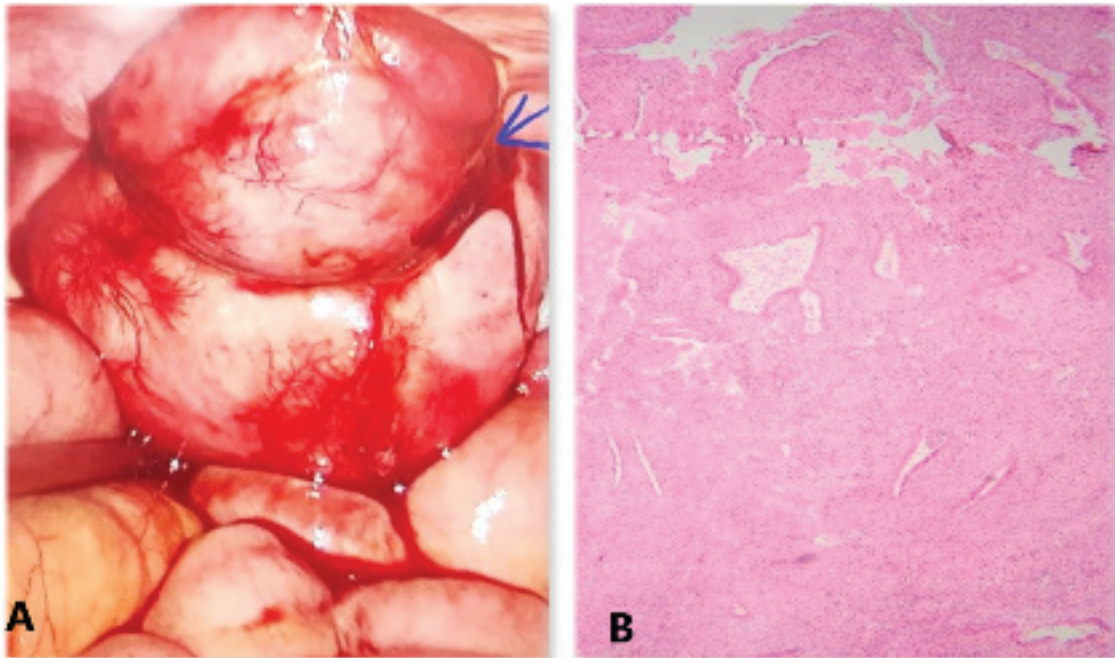
**Received:** 20 July, 2022 **Accepted:** 05 October, 2022



**Address for Correspondence:** Sangam Jha  
e.mail: sangam.jha78@gmail.com ORCID: 0000-0002-4349-1589

©Copyright 2023 by the Turkish-German Gynecological Education and Research Foundation - Available online at [www.jtgg.org](http://www.jtgg.org)  
Journal of the Turkish-German Gynecological Association published by Galenos Publishing House.

DOI: 10.4274/jtgg.galenos.2022.2022-6-1



**Figure 1. (A) A 7x5 cm organized mass attached to the fundus of the uterus, arrow showing trickling of blood from the mass. (B) Hematoxylin and eosin stained section from tumor tissue showing endometrial glands embedded in the myometrium (x100)**

Computed tomography would be helpful in identifying bleeding vessels and to exclude other intra-abdominal pathology. Surgery, either hysterectomy or adenomyomectomy, remains the mainstay of treatment. Zhang et al. (3) reported a similar case of hemoperitoneum caused by bleeding from adenomyosis which was managed with hysterectomy. However, in the present case we performed uterine preserving surgery as the patient was young and desirous of pregnancy.

Though extremely rare, the possibility of adenomyoma should be kept in mind, while evaluating cases of hemoperitoneum in reproductive age women. Early surgical intervention is recommended to establish the diagnosis, control the hemorrhage and decrease the associated morbidity and mortality.

**Sangam Jha, Shalini Singh, Akanksha Singh**

**Department of Obstetrics and Gynecology, All India Institute of Medical Sciences, Patna, India**

## References

1. Peng CR, Chen CP, Wang KG, Wang LK, Chen YY, Chen CY. Spontaneous rupture and massive hemoperitoneum from uterine leiomyomas and adenomyosis in a nongravid and unscarred uterus. *Taiwan J Obstet Gynecol* 2015; 54: 198-200.
2. Emanuele C, Maria C S, Carla E, Giorgio L G, Michele G LG. Difficult diagnosis of hemoperitoneum in a patient with a pelvic mass of large size. *International Journal of Surgery Case Reports* 2016; 26: 197-8.
3. Zhang SX, Wu L, Hou YF, Yan B, Yang SY, Yang LH, et al. Hemoperitoneum caused by bleeding of adenomyosis: a case report. *Clin Exp Obstet Gynecol* 2021; 48: 444-7.
4. Zhang Y, Zhao Y Y, Wei Y, Li R, Qiao J. Spontaneous rupture of subserous uterine vein during late pregnancy after in vitro fertilization. *Fertil Steril* 2009; 92: e13-e16.
5. Yao F, Ding H, Yan H, Zhang F, Wang N. Spontaneous hemoperitoneum in pregnancy. *Taiwan J Obstet Gynecol* 2021; 60: 796-7.