

Prenatal diagnosis of fetal ovarian cyst: case report and review of the literature

Fetal over kistinin prenatal tanısı: olgu sunumu ve literatürün gözden geçirilmesi

Onur Erol¹, Melek Büyükkınacı Erol², Bekir Sıtkı İsenlik¹, Servet Özkiraz³, Mehmet Karaca¹

¹Department of Obstetrics and Gynecology, Antalya Education and Research Hospital, Antalya, Turkey

²Department of Obstetrics and Gynecology, Medstar Hospital, Antalya, Turkey

³Department of Neonatology, Antalya Education and Research Hospital, Antalya, Turkey

Abstract

Foetal ovarian cysts are the most frequently encountered intra-abdominal cystic masses diagnosed prenatally. The aetiology of foetal ovarian cysts is still unknown, but hormonal stimulation is generally considered to be responsible for the disease. The diagnosis is made by the exclusion of other cystic lesions confined to the foetal abdomen.

In this article we report antenatally-detected foetal ovarian cyst with a review of the available literature. Antenatal ultrasonography (USG) revealed an abdominal cystic mass 41x33 mm in diameter in a 33-week gestation female foetus. The normal anatomy of other foetal abdominal organs suggested that an ovarian cyst was the most likely diagnosis. In the antenatal follow-up period, the cyst diameter increased with time. After delivery, USG scan confirmed the antenatal findings. Due to abdominal distension and respiratory distress, ovarian cystectomy was performed on the second postnatal day. The histopathological evaluation of the surgical material reported a serous cystadenoma of the ovary with non-malignant properties.

(J Turkish-German Gynecol Assoc 2013; 14: 119-22)

Key words: Ovarian cyst, prenatal diagnosis, histological examination

Received: 11 August, 2012

Accepted: 14 October, 2012

Özet

Fetal over kistleri, prenatal dönemde tanı konulan kistik abdominal kitleler arasında en sık gözüken yapıdır. Etiyolojisi halen bilinmemekle birlikte, hormonal stimülasyon genellikle bu durumdan sorumlu tutulmaktadır. Fetal batın içinde yerleşen diğer kistik lezyonların dışlanmasıyla tanısı konulmaktadır.

Bu makalede antenatal saptanan fetal over kisti olgusu literatürün gözden geçirilmesiyle birlikte sunulmuştur. Otuz üç haftalık dişi bir fetusta, yapılan antenatal ultrasonografide (USG) 41x33 mm boyutunda abdominal kistik kitle saptandı. Diğer fetal abdominal yapıların normal olması, tanının over kaynaklı kist olduğunu kuvvetlendirdi. Antenatal takipler sırasında kist çapında zamanla artış saptandı. Postnatal dönemde yapılan USG, antenatal dönemdeki bulguları doğruladı. Yenidoğanda abdominal distansiyon ve solunum sıkıntısı gelişmesi üzerine ovarian kistektomi uygulandı. Histopatolojik inceleme sonucu over kistinin, malign özelliği olmayan seröz kistadenom olduğu rapor edildi. (J Turkish-German Gynecol Assoc 2013; 14: 119-22)

Anahtar kelimeler: Over kisti, prenatal tanı, histolojik inceleme

Geliş Tarihi: 11 Ağustos 2012

Kabul Tarihi: 14 Ekim 2012

Introduction

Foetal ovarian cysts are the most commonly diagnosed abdominal tumours in the prenatal period (1). They are usually unilateral, and diagnosed in the third trimester.

Although the aetiology is still unknown, hormonal stimulation is generally considered to be responsible for the disease (foetal gonadotropins, maternal oestrogen and placental human chorionic gonadotropin). The decrease of hormonal stimulation after delivery may lead to spontaneous resolution of the cyst. Abnormal development due to the disruption of vascularisation in primitive gonad, foetal hypothyroidism, congenital adrenal hyperplasia, mutation of the G protein α -subunit, and increased placental chorionic gonadotropin levels in complicated pregnancies such as in diabetes, pre-

eclampsia and Rh isoimmunisation have been so far reported to contribute to the development of these cysts (2-6). Foetal and maternal ovarian cysts may co-exist and could potentially have a similar hormonal aetiology (7).

Renal cyst, hydronephrosis, megacystis, anorectal atresia, urachal cyst, meconium pseudocyst, hydrometrocolpos, mesenteric cyst, liver and splenic cyst may also cause cystic masses in the foetal abdomen; therefore, a differential diagnosis should be established in these circumstances.

Case Report

A primigravid 19-year-old woman was referred to our prenatal centre at 33 weeks of gestation following the ultrasonographic detection of a foetal cystic mass in the abdomen. The



past medical history and antenatal course were unremarkable. Ultrasound examination demonstrated normal anatomy of the bladder, kidneys, liver and intestine in a female foetus. The cyst measured 41x 33 mm in diameter, had anechoic content and the thin wall was located in the lower foetal abdomen; these features suggested a simple ovarian cyst (Figure 1). The patient was informed about the condition and serial ultrasonographic scans were performed every 2 weeks until birth. Cyst diameter was increased to 55x53 mm, 75x56 mm and 82x63 mm at 35, 37 and 39 weeks of gestation, respectively. Caesarean section was performed because of breech presentation at term and a healthy female infant weighing 3040 grams with Apgar scores of 8 and 10 (after 5 and 10 minutes, respectively) was delivered. Abdominal ultrasonographic scan performed on the first postnatal day revealed a cystic mass of 85x85 mm in diameter. Due to severe abdominal distension and respiratory distress, laparotomy was recommended on the second postnatal day. During the surgical procedure, a yellow cystic structure in the right lower quadrant arising from the right ovary was seen (Figure 2); the pedicle was not twisted and the left ovary and adnexal structures were normal in appearance. Cystectomy of the right ovary was carried out. The histopathological examination revealed a large yellowish cystic mass with a diameter of 90x90 mm filled with serous fluid. Final pathological report concluded a serous cystadenoma of the right ovary (Figure 3). On the 5th day after surgery, the newborn had undergone an uncomplicated postoperative course and was discharged with her mother.

Discussion

The incidence of foetal ovarian cyst is uncertain but has been estimated at 1 in 2.625 pregnancies (8). The increased use of routine USG has led to the earlier detection of foetal ovarian cysts. The first case detected by USG was reported in 1975 (9); the earliest case was described in the 19th week of gestation (10). Most cysts are small and involute within the first few months of life.

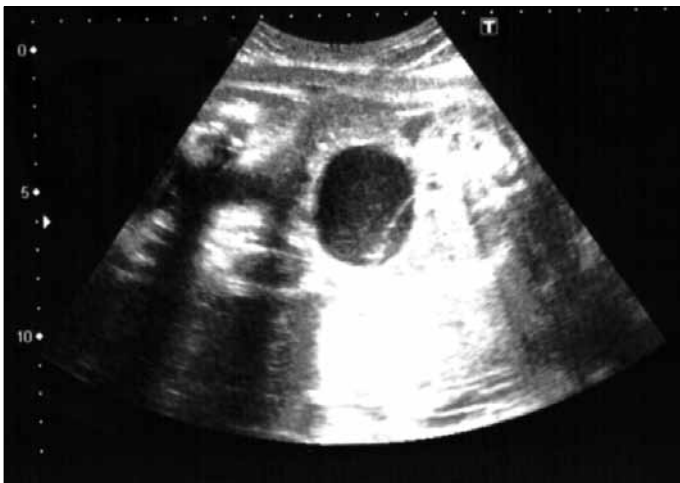

Figure 1. The ultrasound finding of ovarian cyst with a diameter of 41x33 mm at 33 weeks gestation

Magnetic resonance imaging (MRI) is able to visualise ovarian cysts *in utero* by providing exact characterisation through supplemental findings like superior soft tissue contrast, but USG represents the diagnostic standard for imaging in the perinatal period (11). Moreover, a sonographic clue for the diagnosis of foetal ovarian cysts, termed as “daughter cyst sign”, was reported. Within the foetal ovarian cyst, a single, round, anechogenic structure adjacent to the cyst wall was found. This feature confirmed the ovarian origin of the cyst with a sensitivity of 82% and specificity of 100% (12).

Foetal ovarian cyst are classified according to ultrasonographic criteria into two groups: simple (uncomplicated) and complex (complicated) (11). The characteristics of ultrasonographic appearance of simple cysts are the following: unilocular, anechogenic, round, small size (often <5 cm), unilateral or seldom bilateral and thin-walled. Complex cysts on the other hand

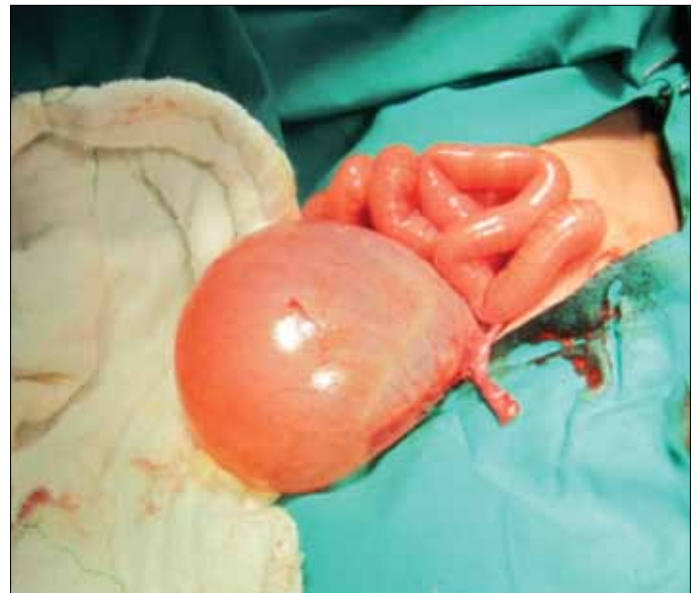

Figure 2. Intraoperative appearance of cyst

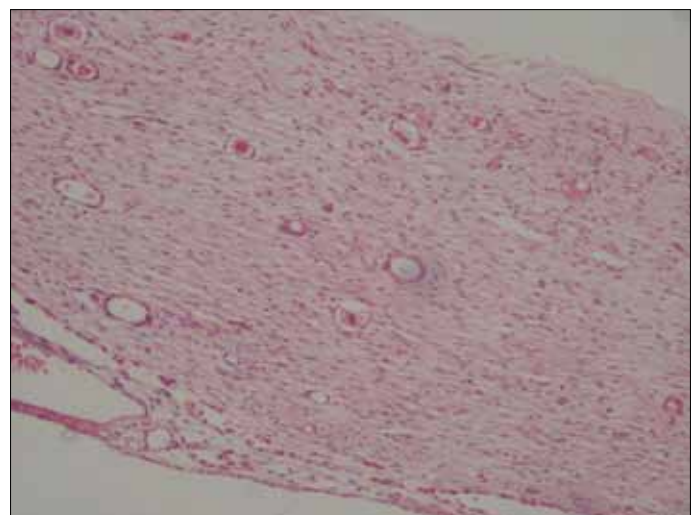


Figure 3. Light microscopy finding in the cyst wall that shows columnar epithelium (H&E, x100)

are thick-walled, containing hyperechogenic components and free-floating material with intracystic septations. Cyst diameter and echogenicity are the main criteria for establishing prognosis. Serial ultrasonographic examination to detect any structural changes in size, appearance or complications is important during the prenatal period. In accordance with the literature, our case report shows that current prenatal USG provides sufficient diagnosis of ovarian cyst.

Various complication associated with foetal ovarian cysts may occur including rupture, haemorrhage, ascites, compression of other viscera and ovarian torsion. Torsion and haemorrhage may lead to loss of the cystic gonad. Rare complications like oedema of the labia and moderate ascites in a foetus with true hermaphroditism, spontaneous haemorrhage into a foetal ovarian cyst, transient ascites, autoamputation, or polyhydramnios as a result of intestinal obstruction were also reported (13-16). Torsion is one of the most serious complications that occur more frequently during foetal life than post-natally. It may be seen antenatally in up to 38-55% of cases and 50-78% during the neonatal period (17). Torsion may also result in adhesion of the ovary to the bowel or other pelvic organs. Sonographic findings of adnexal torsion are not specific. A possible sign of torsion is foetal tachycardia, probably because of peritoneal irritation. Haemorrhage within a cyst is usually found in association with torsion; therefore imaging methods (USG or MRI) may not be able to distinguish these complications (18, 19). There are contradictory reports between size of the cyst, length of the ovarian pedicle and the risk of torsion as well as haemorrhage (1, 11, 20). Long-term outcome after perinatal ovarian torsion is unknown. Haemorrhage within a cyst is another important complication. In a review of 82 foetal ovarian cases, poor outcome linked to ultrasonographic signs of intracystic haemorrhage was stated (21).

The question of perinatal management of ovarian cysts is not clearly answered and is seldom based on the clinical status of the patient. In addition, clinical management varies widely among different centres. Prenatal or postnatal aspiration, neonatal surgery and simple USG monitoring are acceptable with the main objective of preserving ovarian parenchyma.

In most cases, simple cysts tend to regress spontaneously in a sonographic follow-up period. Conservative approaches with serial USG monitoring are recommended according to a case report series by Sanchez et al. (22). The rate of spontaneous resolution of simple cyst is higher than that of complex cysts; some investigators have recommended conservative management for all types of cysts regardless of their sonographic appearance (23, 24). In the postnatal period, no surgical intervention may be needed if the cyst regresses spontaneously. The importance of visualisation of the course of the ovarian cyst was stated in our case. Although the cyst was simple with a small size initially, a progressive increase in cyst size became more evident during the follow-up period.

The importance of aspiration of ovarian cysts exceeding a 40 mm diameter was reported by Noia et al. (25). The authors emphasised that aspiration of ovarian cysts allows a good longitudinal treatment of foetal affection, thus avoiding torsion, tissue necrosis and postnatal surgery. The suggested threshold

size for prenatal aspiration of simple cysts varied from 30 to 50 mm in most reports (17, 20). Complications of large cysts include the impairment of spontaneous delivery, distension of the foetal abdomen and disruption of the foetal heart function. Prenatal puncturing is reasonable under these conditions before birth, but risks of preterm labour, chorioamnionitis, foetal injury and foetal pain are of concern (18). Recession of functional abnormalities in foetal echocardiography after prenatal aspiration of a foetal ovarian cyst was also noted (26). Another consideration of puncturing is intracystic bleeding, which can lead to subsequent diagnostic difficulties and the possibility of foetal malignant ovarian tumour (4, 10). An additional advantage of this procedure is performing a hormonal and cytological analysis of the cyst fluid, eliminating the need for laparotomy on a newborn. In some circumstances, the hole produced by aspiration closes again and the cyst reforms. There has been no published randomised trial comparing prenatal aspiration of the cysts with any kind of postnatal management.

There are controversial reports about the postnatal surgery indication. The list of major indications of surgery include: complex cysts that showed evidence of torsion post-natally, the persistence of large cyst in a follow-up period, the suspicion of neoplastic tumour and clinical symptoms in the newborn like abdominal distension, bowel obstruction or torsion. Abdominal distension and respiratory distress due to a large-sized ovarian cyst with compression of other visceral organs was determined in our case. Benefits of surgical management include the definite removal of the cyst for optimal ovarian preservation and separation of any adhesions between ovaries and pelvic organs. Dimitraki et al. (27) suggested treatment of symptomatic cysts or cysts with a diameter of >5 cm which do not regress or enlarge, whereas another report suggested neonatal surgery in the case of complex cysts regardless of size or in simple cysts larger than 20 mm in diameter (19). Surgical methods via laparoscopy or laparotomy can be performed depending on the experience of the surgeon. Two-port laparoscopy has been used in the management of foetal ovarian cyst that is cosmetically preferable and allows earlier feeding and recovery (28). Surgical intervention through a Pfannenstiel incision was carried out in the current case due to the large size of the cyst. Ovarian cysts are most often functional and benign tumours; the question of malignancy plays virtually no role in the prenatal diagnosis. In most circumstances the origin is the follicular epithelium, but they can also occur as theca-lutein or corpus luteum cysts. Foetal ovarian carcinoma has been reported by Ziegler in a 30-week foetus (29). A review of the literature reveals that 85-90% of foetal ovarian masses are cystic (follicular or luteinic origins), and 10-15% are organic (3% carcinomas and 7-12% represented by teratomas, and mucinous and serous cystadenomas) (30).

Mode of delivery is not essentially affected by prenatal diagnosis of an ovarian cyst. Today, unless an obstetric indication is present, vaginal delivery is recommended (4, 18).

Long-term outcome of children with ovarian cysts diagnosed prenatally is limited. A higher rate of ovarian loss was noted in children whose prenatal USG showed a simple ovarian cyst that became complex in postnatal scans. Long-term pelvic

ultrasound follow-up in order to monitor the integrity of pelvic organs was recommended (31).

Finally, a foetal ovarian cyst is not a life-threatening condition. They are usually simple and small in size. After diagnosis, they must be followed by serial ultrasonographic examinations.

Ethics Committee Approval: *Ethics committee approval was received for this study.*

Informed Consent: *Written informed consent was obtained from the patient for publication of this case report and any accompanying images.*

Peer-review: *Externally peer-reviewed.*

Author contributions: *Concept - O.E.; Design - S.Ö.; Supervision - O.E.; Resource - M.K.; Materials - O.E.; Data Collection&/or Processing - B.S.İ.; Analysis&/or Interpretation - M.B.E.; Literature Search - O.E.; Writing - O.E.; Critical Reviews - O.E.*

Conflict of Interest: *No conflict of interest was declared by the authors.*

Financial Disclosure: *No financial disclosure was declared by the authors.*

References

- Crombleholme TM, Craigo SD, Garmel S, Alton ME. Fetal ovarian cyst decompression to prevent torsion. *J Pediatr Surg* 1997; 32: 1447-9. [\[CrossRef\]](#)
- Enríquez G, Durán C, Torán N, Piqueras J, Gratacós E, Aso C, et al. Conservative versus surgical treatment for complex neonatal ovarian cysts: outcomes study. *AJR Am J Roentgenol* 2005; 185: 501-8. [\[CrossRef\]](#)
- Hasiakos D, Papakonstantinou K, Bacanu AM, Argeitis J, Botsis D, Vitoratos N. Clinical experience of five fetal ovarian cysts: diagnosis and follow-up. *Arch Gynecol Obstet* 2008; 277: 575-8. [\[CrossRef\]](#)
- Shimada T, Miura K, Gotoh H, Nakayama D, Masuzaki H. Management of prenatal ovarian cysts. *Early Hum Dev* 2008; 84: 417-20. [\[CrossRef\]](#)
- Jafri SZ, Bree RL, Silver TM, Ouimette M. Fetal ovarian cysts: sonographic detection and association with hypothyroidism. *Radiology* 1984; 150: 809-12.
- Gaspari L, Paris F, Nicolino M, Hameury F, Bonnaure H, Pienkowski C et al. Fetal ovarian cysts: an early manifestation of McCune-Albright syndrome? *Prenat Diagn* 2012; 32: 859-63.
- Francis SA, Heazell AE, Chakravorty S, Rhodes C. Concurrent maternal and fetal ovarian cysts. *J Matern Fetal Neonatal Med* 2010; 23: 555-7. [\[CrossRef\]](#)
- Kirkinen P, Jouppila P. Perinatal aspects of pregnancy complicated by fetal ovarian cyst. *J Perinat Med* 1985; 13: 245-51. [\[CrossRef\]](#)
- Valenti C, Kassner G, Yermakow V, Cromb E. Antenatal diagnosis of a fetal ovarian cyst. *Am J Obstet Gynecol* 1975; 123: 216-9.
- Meizner I, Levy A, Katz M, Maresh AJ, Glezerman M. Fetal ovarian cysts: prenatal ultrasonographic detection and postnatal evaluation and treatment. *Am J Obstet Gynecol* 1991; 164: 874-8. [\[CrossRef\]](#)
- Nussbaum AR, Sanders RC, Hartman DS, Dudgeon DL, Parmley TH. Neonatal ovarian cysts. sonographic-pathologic correlation. *Radiology* 1988; 168: 817-21.
- Lee HJ, Woo SK, Kim JS, Suh SJ. "Daughter cyst" sign: a sonographic finding of ovarian cyst in neonates, infants, and young children. *AJR Am J Roentgenol* 2000; 174: 1013-5. [\[CrossRef\]](#)
- Nitzsche K, Kamin G, Dittert DD, Bier A, Distler W. Fetal juvenile granulosa cell tumor with hermaphroditism versus - prenatal diagnosis, management and outcome. *Ultraschall Med* 2009; 30: 404-7. [\[CrossRef\]](#)
- Abolmakarem H, Tharmaratnum S, Thilaganathan B. Fetal anemia as a consequence of hemorrhage into an ovarian cyst. *Ultrasound Obstet Gynecol* 2001; 17: 527-8. [\[CrossRef\]](#)
- Degani S, Lewinsky RM. Transient ascites associated with a fetal ovarian cyst. *Case report Fetal Diagn Ther* 1995; 10: 200-3. [\[CrossRef\]](#)
- Amodio J, Hanano A, Rudman E, Banfro F, Garrow E. Complex left fetal ovarian cyst with subsequent autoamputation and migration into the right lower quadrant in a neonate: case report and review of the literature. *Ultrasound Med* 2010; 29: 497-500.
- Giorlandino C, Bilancioni E, Bagolan P, Muzii L, Rivoecchi M, Nahom A. Antenatal ultrasonographic diagnosis and management of fetal ovarian cysts. *Int J Gynaecol Obstet* 1994; 44: 27-31. [\[CrossRef\]](#)
- Heling KS, Chaoui R, Kirchmair F, Stadie S, Bollmann R. Fetal ovarian cysts: prenatal diagnosis, management and postnatal outcome. *Ultrasound Obstet Gynecol* 2002; 20: 47-50. [\[CrossRef\]](#)
- Monnery-Noché ME, Auber F, Jouannic JM, Bénifla JL, Carbonne B, Dommergues M, et al. Fetal and neonatal ovarian cysts: is surgery indicated? *Prenat Diagn*. 2008; 28: 15-20. [\[CrossRef\]](#)
- Perrotin F, Potin J, Haddad G, Sembely-Taveau C, Lansac J, Body G. Fetal ovarian cysts: a report of three cases managed by intrauterine aspiration. *Ultrasound Obstet Gynecol* 2000; 16: 655-9. [\[CrossRef\]](#)
- Galinier P, Carfagna L, Juricic M, Lemasson F, Moscovici J, Guitard J, et al. Fetal ovarian cysts management and ovarian prognosis: a report of 82 cases. *J Pediatr Surg* 2008; 43: 2004-9. [\[CrossRef\]](#)
- Sánchez P, Gámez F, de León-Luis J, Antonio Carrillo J, Martínez R. Fetal ovarian cyst: prenatal diagnosis, perinatal outcome and treatment. Case series and literature review. *Ginecol Obstet Mex* 2012; 80: 84-90.
- Müller-Leisse C, Bick U, Paulussen K, Tröger J, Zachariou Z, Holzgreve W, et al. Ovarian cysts in the fetus and neonate--changes in sonographic pattern in the follow-up and their management. *Pediatr Radiol* 1992; 22: 395-400. [\[CrossRef\]](#)
- Luzzatto C, Midrio P, Toffolutti T, Suma V. Neonatal ovarian cysts: management and follow-up. *Pediatr Surg Int* 2000; 16: 56-9. [\[CrossRef\]](#)
- Noia G, Riccardi M, Visconti D, Pellegrino M, Quattrocchi T, Tintoni M, et al. Invasive fetal therapies: approach and results in treating fetal ovarian cysts. *J Matern Fetal Neonatal Med* 2012; 25: 299-303. [\[CrossRef\]](#)
- Ślodki M, Janiak K, Szaflik K, Wilczyński J, Oszukowski P, Chilarski A, et al. Fetal echocardiography in fetal ovarian cysts. *Ginekol Pol* 2008; 79: 347-51.
- Dimitraki M, Koutlaki N, Nikas I, Mandrati T, Gourovanidis V, Kontomanolis E, et al. Fetal ovarian cysts. Our clinical experience over 16 cases and review of the literature. *J Matern Fetal Neonatal Med* 2012; 25: 222-5. [\[CrossRef\]](#)
- Visnjic S, Domljan M, Zupancic B. Two-port laparoscopic management of an autoamputated ovarian cyst in a newborn. *J Minim Invasive Gynecol* 2008; 15: 366-9. [\[CrossRef\]](#)
- Ziegler EE. Bilateral ovarian carcinoma in a 30 week fetus. *Arch Pathol (Chic)* 1945; 40: 279-82.
- Henron R, Helardot PG. In utero diagnosis of cysts of the ovary. *Ann Pediatr (Paris)* 1987; 34: 65-9.
- Ben-Ami I, Kogan A, Fuchs N, Smorgick N, Mendelovic S, Lotan G, et al. Long-term follow-up of children with ovarian cysts diagnosed prenatally. *Prenat Diagn* 2010; 30: 342-7.