

# Conservative laparoscopic management of adnexal torsion

## *Adneks torsiyonunda konservatif laparoskopik yaklaşım*

Rana Karayalçın<sup>1</sup>, Sarp Özcan<sup>1</sup>, Şebnem Özyer<sup>1</sup>, Turgut Var<sup>1</sup>, Hüseyin Yeşilyurt<sup>1</sup>, Hüseyin Dumanlı<sup>2</sup>, Sunullah Soysal<sup>1</sup>, Leyla Mollamahmutoğlu<sup>1</sup>, Sertaç Batoğlu<sup>1</sup>

<sup>1</sup>Department of Obstetrics and Gynecology, Zekai Tahir Burak Women's Health Education and Research Hospital, Ankara, Turkey

<sup>2</sup>Department of Radiology, Zekai Tahir Burak Women's Health Education and Research Hospital, Ankara, Turkey

### Abstract

**Objective:** To evaluate our experience with adnexal torsion (AT) in 36 patients and the outcomes of the patients who were managed conservatively via laparoscopy.

**Material and Methods:** A prospective study was conducted on 36 patients who underwent operations for AT via laparoscopy between January 2008 and December 2009. Data including age, previous history, time of onset of symptoms, time of admission to hospital, gray-scale and color Doppler US findings, time interval between hospital admission and surgery, type of intervention, operative findings and postoperative gray-scale and Doppler US findings were recorded.

**Results:** In 29 (80.5%) patients, a preoperative diagnosis of AT was confirmed clinically. The mean age of the patients was 26.5, with a range of 11 to 44. Ovarian blood flow was assessed by color Doppler US ultrasonography in 30 patients preoperatively. In 11 (36.6%) patients, this was found to be normal. In 19 (63.3%) patients, ovarian blood flow was found to be pathological or absent. Laparoscopic conservative treatment was performed in 34 patients. In two patients, salpingo-oophorectomy was performed. No thromboembolic complications were seen. Postoperative ultrasonographic examinations confirmed normal ovarian morphology and Doppler blood flow in all patients with no recurrence.

**Conclusion:** Early diagnosis and treatment are key factors in managing AT. According to the results of the present study, given its demonstrated safety and benefits, in women of reproductive age, a conservative approach of untwisting the adnexa and salvaging the ovary via laparoscopy should be considered in AT cases in which the time from the onset of symptoms to surgery does not exceed 44 hours, regardless of the color and number of twists.

(J Turkish-German Gynecol Assoc 2011; 12: 4-8)

**Key words:** Adnexal torsion, laparoscopy, detorsion, conservative management, ultrasonography

**Received:** 20 November, 2010

**Accepted:** 17 December, 2010

### Özet

**Amaç:** Laparoskopi ile konservatif yaklaşım uyguladığımız 36 adneksiyal torsiyon (AT) hastasının sonuçlarını belirlemek.

**Gereç ve Yöntemler:** Ocak 2008-Aralık 2009 tarihleri arasında prospektif olarak planlanan çalışmada 36 hastanın verileri (yaş, önceki hikaye, semptom başlangıç zamanı, hastaneye başvuru süresi, USG bulguları, hasteneye başvurudan cerrahiye kadar geçen süre, yapılan girişim ve operatif bulgular ile postoperatif USG ve Doppler bulguları) belirtilmiştir.

**Bulgular:** Yirmidokuz hastada (%80.5) klinik olarak AT tanısı konulmuştur. Hastaların ortalama yaşı 26.5. Otuz hastada preoperatif doppler USG yapılmıştır. Onbir hastada doppler normaldir (%36.6). 19 hastada dopplerde patolojik kan akımı veya akım yokluğu gözlenmiştir (%63.3). 2 hastaya salpingooferektomi yapılmıştır. Tüm vakalarda postoperatif doppler normal olarak bulunmuş ve rekürrens gözlenmemiştir.

**Sonuç:** AT da erken tanı ve tedavi over fonksiyonları açısından çok önemlidir. L/S ile overin detorsiyonu semptom başlangıcından sonra 44. saate kadar mümkündür.

(J Turkish-German Gynecol Assoc 2011; 12: 4-8)

**Anahtar kelimeler:** Adneksiyal torsiyonu, laparoskopi, detorsiyon, konservatif yaklaşımı, ultrasonografi

**Geliş Tarihi:** 20 Kasım 2010

**Kabul Tarihi:** 17 Aralık 2010

### Introduction

Adnexal torsion (AT), the twisting of an ovary and/or tube on its ligamentous support, is the fifth most common gynecological emergency (1), accounting for 3% of all gynecological surgical emergencies (2, 3). Torsion of the adnexa initially interferes with the venous and lymphatic circulation. If unrelieved, it progresses rapidly to occlusion of the arterial

circulation, eventually leading to gangrene and hemorrhagic necrosis (4). It occurs most frequently in adolescent girls and women of childbearing age, most of whom desire future fertility (5). Delay and misdiagnosis of AT are common and can result in a functional loss of the ovary (2).

For approximately 100 years after its initial description in the American literature by J. Bland Sutton, AT was treated by performing a salpingo-oophorectomy without untwisting the adnexa to

avoid potential thromboembolism from ovarian vein thrombosis (6). However, a significant association between thromboembolism and detorsion of an ischemic pedicle has never been established (7). In the last 15 years, many reports describe minimally invasive surgery with laparoscopy, detorsion, and preservation of the ovary, which has currently shifted the standard approach from oophorectomy to laparoscopy (2, 8-13). As these patients tend to be young, and future fertility is desired, conservative management seems a feasible choice and preferable approach.

The purpose of this study was to evaluate our experience with AT in 36 patients and the outcomes of the patients who were managed conservatively via laparoscopy.

## Materials and Methods

A prospective study was conducted on 36 patients who underwent operations for AT via laparoscopy between January 2008 and December 2009. The study was approved by the institutional review board. The demographic data, including age, gravidity, parity, marital status, and previous history, were noted. The time of onset of symptoms, time of admission to hospital, gray-scale ultrasonographic (US) findings, color Doppler US (ALOKA FSSD-5500) findings including the presence of fluid in the Douglas pouch, diameter and appearance of the ovary, presence of hyperstimulation, edema of the parenchyma, presence of an ovarian cyst, time interval between hospital admission and surgery, type of intervention, and operative findings including duration of the operation, size of the ovary and presence of other pelvic pathologies were recorded. All the patients underwent laparoscopic management. Follow-up gray-scale and color Doppler US were performed during the first week and again following the first and sixth month of laparoscopy for patients who were conservatively managed to determine the outcome of the adnexa.

## Results

Thirty-six AT cases were managed by laparoscopy between January 2008 and December 2009. In 29 (80.5%) patients, a preoperative diagnosis of AT was confirmed clinically, and a laparoscopy was performed immediately. In the remainder of the patients, the preoperative diagnosis included ovarian cysts, ruptured ovarian cysts and tubo-ovarian abscesses. The mean age of the patients was  $26.5 \pm 4.82$ , with a range of 11 to 44 years. The mean gravidity and parity was  $2.4 \pm 0.98$  (0-5) and  $1.8 \pm 0.6$  (0-3) respectively. Twenty-eight of the women were married. Two women had undergone ovarian stimulation during infertility treatments as part of an in vitro fertilization-intracytoplasmic sperm injection (IVF-ICSI) program and became pregnant on their first attempt; torsion occurred in the 11th to 12th week of their pregnancies. The most common presenting signs were lower abdominal pain as well as nausea and vomiting, which were observed in 33 (91.6%) patients and 29 (80.5%) patients, respectively. Leukocytosis was detected in 27 (75%) patients. All patients underwent ultrasonography preoperatively, and a pelvic mass was detected in all cases. The mean diameter of the mass was  $7.2 \pm 2.21$  cm, with a range of 5 to 14 cm. In 23 (63.8%) patients, torsion occurred on the right side. Ovarian blood flow was assessed by color Doppler US in 30 patients

preoperatively. In 11 (36.6%) patients, it was found to be normal while in 19 (63.3%) patients, ovarian blood flow was found to be pathological or absent. The average time from the onset of symptoms to operation was  $26 \pm 6.44$  hours, with a range of 8 to 44 hours. The average time from hospital admission to operation was  $8.4 \pm 3.88$  hours. Laparoscopic conservative treatment was performed in 34 patients. In all 34 patients, detorsion of the adnexa and oophoropexy were performed. Oophoropexy was performed by fixing the utero-ovarian ligament to the sacro-uterine ligament, except in two pregnant women, in whom the ligaments were fixed to the pelvic sidewall with two stitches using nonabsorbable 0 prolene sutures. Nine patients underwent an ovarian cystectomy. Pathological examination revealed serous cyst, paraovarian cyst and dermoid cyst in four, three and two patients respectively. Pathological surgical findings are listed in Table 1. Demographic data, symptoms, signs, and ultrasonographic and Doppler findings of the patients are summarized in Table 2. In two patients, salpingo-oophorectomy was performed.

**Table 1. Pathological surgical findings**

Pathological finding	n	%
Serous cyst	4	11.1
Paraovarian cyst	3	8.3
Dermoid cyst	2	5.5
Fibroma	1	2.7
Normal ovary	1	2.7

**Table 2. Demographic data, symptoms, signs, ultrasonographic and Doppler findings of patients**

Data	
Age (years, mean $\pm$ SD)	26.5 $\pm$ 4.82
Gravidity (n, mean $\pm$ SD)	2.4 $\pm$ 0.98
Married (n,%)	28 (77.7%)
Infertility treatment (n,%)	2 (5.5%)
Symptoms and signs	
Nausea (n,%)	33 (91.6%)
Vomiting (n,%)	29 (80.5%)
Leukocytosis (n,%)	27 (75%)
Ultrasonographic findings	
Diameter of the mass (cm, mean $\pm$ SD)	7.2 $\pm$ 2.21
Right sided torsion (n, %)	23 (63.8%)
Pathologic or absent blood flow on Doppler US (n,%)	19 (63.3%)
Normal blood flow on Doppler US (n,%)	11 (36.6%)
Time from hospital admission to operation (hr, mean $\pm$ SD)	8.4 $\pm$ 3.88
Time from onset of symptoms to operation (hr, mean $\pm$ SD)	26 $\pm$ 6.44
Conservative treatment (n, %)	34 (94.4%)
Oophorectomy (n,%)	2 (5.5%)

Both of these patients were postmenopausal. Pathological examination revealed normal ovary with hemorrhagic infarction findings in one of these patients and torsioned ovarian fibroma in the other patient. All the patients had uneventful recoveries in the postoperative period. No thromboembolic complications were seen. Patients were discharged one to two days after the laparoscopies. Follow-up gray-scale and Doppler US were performed for all 34 patients in the first week, the first month and the sixth month following surgery. First year controls were completed in 26 patients, which revealed normal US findings. First week controls were performed in 34 patients which revealed a mean ovarian diameter of 5.2 cm on gray-scale US and normal Doppler US findings. First month controls revealed normal ovarian morphology on gray-scale US and normal Doppler US findings in all non-pregnant patients, however gray-scale US revealed a mean ovarian diameter of 5.5 cm at the end of the first month in two pregnant patients. Normal morphology was attained in the third month visit in the pregnant patients. Doppler blood flow was normal in all patients with no recurrence.

Sonographic pictures pre and postoperative ovary are given in Figure 1 and 2 respectively. Figure 1 demonstrates the torsioned ovary with no blood flow and Figure 2 demonstrates the detorsioned ovary revealing normal blood on Doppler US.

In one of the pregnant patients who were treated conservatively due to ovarian torsion, the ovary was observed as completely normal in size and localization during a cesarean section.

## Discussion

Because most cases of AT occur in reproductive-age women, prompt diagnosis and treatment is important for the preservation of ovarian function. More than 80% of all cases occur in women under 50. Although cysts and neoplasms account for over 90% of cases, torsion can also occur in ovaries that appear normal (8). Ovulation induction with gonadotropins predisposes the patient to torsion because of ovarian enlargement (3, 14-16).

Delays in diagnosis and surgical intervention are relatively common with AT because there is a non-specific presentation of cases and no absolute clinical profile. The time span from the onset of symptoms to operation reportedly varies from several hours to several days (17). The diagnosis of AT is presently based on clinical symptoms and a physical examination. Blood tests and imaging techniques contribute little to a preoperative diagnosis. The majority of patients present with a sudden onset of lower abdominal pain often associated with nausea and vomiting, adnexal mass, fever, and leukocytosis (8-10, 14). Pain relief observed during observation may be the result of perceptive nerve death and tissue degeneration in the affected ovary (17, 18). Bouguizane et al. reported that 57.8% of patients were diagnosed accurately at the first clinical examination in their study (19). Bar-On et al. found that women who underwent laparoscopies for suspected AT were correctly diagnosed in less than half of the cases (46.1%) (5).

Doppler US studies have been investigated extensively in the diagnosis of AT. A review of surgically diagnosed ovarian torsion cases by Pena et al. demonstrated that normal blood flow

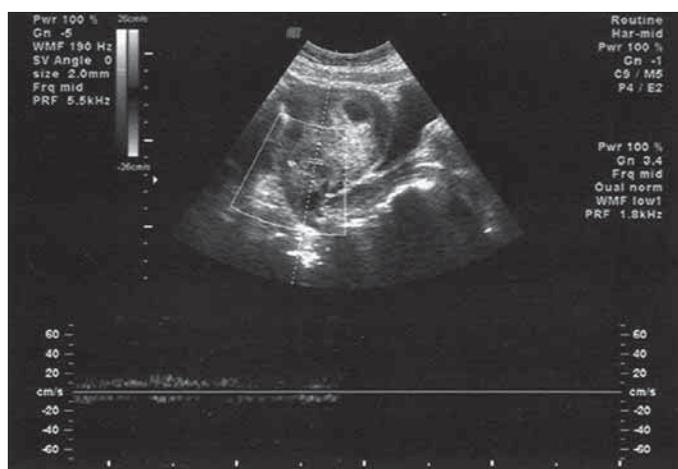


Figure 1. Torsioned ovary with no blood flow on Doppler US

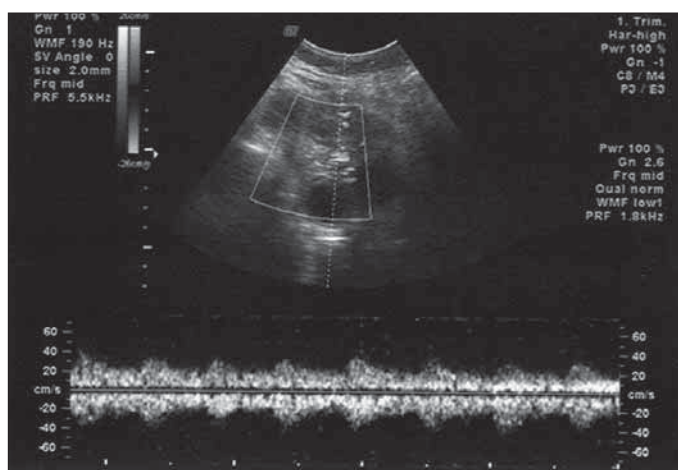


Figure 2. Detorsioned ovary with normal blood flow on Doppler US

was found in 60% of such cases (20). Therefore, the presence of blood flow should not exclude a diagnosis of torsion when there is a high clinical suspicion. Although the absence of Doppler flow is highly specific, it has a very low sensitivity in diagnosing torsion (20, 21). In the Bar-On et al. study, it was found that ovarian blood flow had a low sensitivity (43.8%) and a high specificity (91.7%) for AT (5). In our study, pathological or absent blood flow was found in only 63.3% of the patients. These findings support the continued use of ultrasonographic and Doppler studies as diagnostic aids in cases of suspected AT but warrant caution because of their limited accuracy.

When AT is suspected, an emergency laparoscopy should be performed to establish an accurate diagnosis and avoid ovarian damage. We found that 80.5% of the patients were accurately diagnosed as having AT before undergoing laparoscopy. Many investigators have attempted to define the viable and nonviable appearance of torsioned adnexa during intraoperative inspection. Several studies have shown that the estimation of the degree of necrosis during surgery is inaccurate (22, 23). The color, size, and edema of the twisted ischemic adnexa usually do not reflect the true degree of damage to ovarian tissue. Oelsner et al. demonstrated that the adnexa can retrieve its

functional integrity, which was shown by the ultrasonographic observation of follicular development (91.3%), the normal macroscopic appearance of the adnexa during subsequent surgical intervention (92.4%), and successful oocyte fertilization in all reported cases (13). Taskin et al. investigated adnexal recovery in rodents (24). All rodent adnexa undergoing surgical torsion for 24 hours displayed normal histological findings despite a black-blue, ischemic appearance immediately and for one week after reversal of the torsion. The black-blue appearance was due to an initial lymphatic and venous stasis rather than significant arterial ischemia (24). In various studies in the literature, it has been reported that ovarian function is preserved in 88% to 100% of cases after detorsion of the twisted adnexa (13, 25-28).

In the past, laparotomy with oophorectomy was the standard treatment for AT. Concerns about possible thromboembolism and irreversible ischemic injuries led to the removal of the affected adnexa, regardless of the patient's age or her desire for future fertility. As early as 1946, Way described 16 cases of torsion that were managed by untwisting the adnexa with no serious complications (29). Oelsner et al. reported that none of the patients in their study of 102 AT cases had clinical signs of thromboembolism postoperatively (13). The incidence of pulmonary embolism was reported in 0.2% of cases with adnexal torsion treated by adnexectomy and not more frequently when the adnexa were untwisted (7). No thromboembolic complications secondary to adnexal detorsion were noted in our patients, as reported in the literature. Because there is no effective clinical method of predicting the viability of an ovary exactly by macroscopic appearance, and normal ovarian morphology and follicle formation have been confirmed in many patients, adnexectomy should be avoided. Removing the injured organ is suggested only when there are obvious signs of adnexal disruption, such as ligament detachment or ovarian tissue decomposition (2). In postmenopausal women, the treatment of choice is bilateral oophorectomy.

In the study by Oelsner et al., 5 of 102 patients (4.9%) had retorsion in the same adnexa (13). Surgical management to prevent the recurrence of AT has included triplication of the utero-ovarian ligament (30), in which the ligament is plicated and shortened with a running stitch; ovariopexy, in which the ovary is sutured to the posterior aspect of the uterus or the lateral pelvic wall; and oophoropexy, in which the utero-ovarian ligament is sutured either to the posterior aspect of the uterus or to the lateral pelvic wall. Although oophoropexy has not been evaluated in randomized trials, the procedure has been performed in women of all ages and during pregnancy (8). In our study, we performed oophoropexy in all conservatively managed cases and there were no recurrences of AT.

This is a prospective study consisting of 34 cases of AT managed conservatively by laparoscopy. Normal ovarian morphology and follicle formation were confirmed in all the cases with no recurrences. There were no postoperative complications or apparent adverse effects. Early diagnosis and treatment are key factors in managing AT. According to the results of the present study, given its demonstrated safety and benefits, a conservative approach of untwisting the adnexa and salvaging the ovary

via laparoscopy should be considered in AT cases in women of reproductive age in which the time from the onset of symptoms to surgery does not exceed 44 hours, regardless of the color and number of twists.

#### Conflict of interest

None declared.

#### References

1. Kupesic S, Plavsic BM (2009) Adnexal torsion: color Doppler and three-dimensional ultrasound. *Abdom Imaging*. Sep 4. [Epub ahead of print].
2. Oelsner G, Shashar D. Adnexal torsion. *Clin Obstet Gynecol*. 2006; 49: 459-63. [\[CrossRef\]](#)
3. Rackow BW, Patrizio P. Successful pregnancy complicated by early and late adnexal torsion after in vitro fertilization. *Fertil Steril*. Mar 2007; 87: 697. [\[CrossRef\]](#)
4. Graif M, Itzhak Y. Sonographic evaluation of ovarian torsion in childhood and adolescence. *AJR Am J Roentgenol*. 1988; 150: 647-9.
5. Bar-On S, Mashiach R, Stockheim D, Soriano D, Goldenberg M, Schiff E et. Emergency laparoscopy for suspected ovarian torsion: are we too hasty to operate? *Fertil Steril*. 2010; 93: 2012-5. [\[CrossRef\]](#)
6. Zweig S, Perron J, Grubb D, Mishell DR Jr. Conservative management of adnexal torsion. *Am J Obstet Gynecol*. 1993; 168: 1791-5.
7. McGovern PG, Noah R, Koenigsberg R, Little AB. Adnexal torsion and pulmonary embolism: case report and review of the literature. *Obstet Gynecol Surv*. 1999; 54: 601-8. [\[CrossRef\]](#)
8. Weitzman VN, DiLuigi AJ, Maier DB, Nulsen JC. Prevention of recurrent adnexal torsion. *Fertil Steril*. 2008; 90: 1-3. [\[CrossRef\]](#)
9. Mashiach S, Bider D, Moran O, Goldenberg M, Ben-Rafael Z. Adnexal torsion of hyperstimulated ovaries in pregnancies after gonadotropin therapy. *Fertil Steril*. 1990; 53: 76-80.
10. Gorkemli H, Camus M, Clasen K. Adnexal torsion after gonadotropin ovulation induction for IVF or ICSI and its conservative treatment. *Arch Gynecol Obstet*. 2002; 267: 4-6. [\[CrossRef\]](#)
11. Ben-Rafael Z, Bider D, Mashiach S. Laparoscopic unwinding of twisted ischemic hemorrhagic adnexum after in vitro fertilization. *Fertil Steril*. 1990; 53: 569-71.
12. Oelsner G, Bider D, Goldenberg M, Admon D, Mashiach S. Long-term follow-up of the twisted ischemic adnexa managed by detorsion. *Fertil Steril*. 1993; 60: 976-9.
13. Oelsner G, Cohen SB, Soriano D, Admon D, Mashiach S, Carp H. Minimal surgery for the twisted ischaemic adnexa can preserve ovarian function. *Hum Reprod*. 2003; 18: 2599-602. [\[CrossRef\]](#)
14. Pinto AB, Ratts VS, Williams DB, Keller SL, Odem RR. Reduction of ovarian torsion 1 week after embryo transfer in a patient with bilateral hyperstimulated ovaries. *Fertil Steril*. 2001; 76: 403-6. [\[CrossRef\]](#)
15. Child TJ, Watson NR, Ledger WL. Sequential bilateral adnexal torsion after a single cycle of gonadotropin ovulation induction with intrauterine insemination. *Fertil Steril*. 1997; 67: 573-5. [\[CrossRef\]](#)
16. Kang HJ, Davis OK, Rosenwaks Z. Simultaneous bilateral ovarian torsion in the follicular phase after gonadotropin stimulation. *Fertil Steril*. 2006; 86: 462. [\[CrossRef\]](#)
17. Houry D, Abbott JT. Ovarian torsion: a fifteen-year review. *Ann Emerg Med*. 2001; 38: 156-9. [\[CrossRef\]](#)
18. White M, Stella J. Ovarian torsion: 10-year perspective. *Emerg Med Australas*. 2005; 17: 231-7. [\[CrossRef\]](#)
19. Bouguizane S, Bibi H, Farhat Y, Dhifallah S, Darraji F, Hidar S et al. Adnexal torsion: a report of 135 cases. *J Gynecol Obstet Biol Reprod (Paris)*. 2003; 32: 535-40.
20. Peña JE, Ufberg D, Cooney N, Denis AL. Usefulness of Doppler sonography in the diagnosis of ovarian torsion. *Fertil Steril*. 2000; 73: 1047-50. [\[CrossRef\]](#)

21. Gordon JD, Hopkins KL, Jeffrey RB, Giudice LC. Adnexal torsion: color Doppler diagnosis and laparoscopic treatment. *Fertil Steril*. 1994; 61: 383-5.
22. Cass DL. Ovarian torsion. *Semin Pediatr Surg*. 2005; 14: 86-92. [\[CrossRef\]](#)
23. Mazouni C, Bretelle F, Ménard JP, Blanc B, Gamberre M. Diagnosis of adnexal torsion and predictive factors of adnexal necrosis]. *Gynecol Obstet Fertil*. 2005; 33: 102-6. [\[CrossRef\]](#)
24. Taskin O, Birincioglu M, Aydin A, Buhur A, Burak F, Yilmaz I et al. The effects of twisted ischaemic adnexa managed by detorsion on ovarian viability and histology: an ischaemia-reperfusion rodent model. *Hum Reprod*. 1998; 13: 2823-7.
25. Mage G, Canis M, Manhes H, Pouly JL, Bruhat MA. Laparoscopic management of adnexal torsion. A review of 35 cases. *J Reprod Med*. 1989; 34: 520-4.
26. Levy T, Dicker D, Shalev J, Dekel A, Farhi J, Peleg D et al. Laparoscopic unwinding of hyperstimulated ischaemic ovaries during the second trimester of pregnancy. *Hum Reprod*. 1995; 10: 1478-80.
27. Shalev E, Bustan M, Yarom I, Peleg D. Recovery of ovarian function after laparoscopic detorsion. *Hum Reprod*. 1995; 10: 2965-6.
28. PanCsky M, Abargil A, Dreazen E, Golan A, Bukovsky I, Herman A. Conservative management of adnexal torsion in premenarchal girls. *J Am Assoc Gynecol Laparosc*. 2000; 7: 121-4.
29. Way S. Ovarian cystectomy of twisted cysts. *Lancet* 1946; 2: 47-8. [\[CrossRef\]](#)
30. Germain M, Rarick T, Robins E. Management of intermittent ovarian torsion by laparoscopic oophoropexy. *Obstet Gynecol*. Oct 1996; 88: 715-7. [\[CrossRef\]](#)