

What is your diagnosis?

A 23-year-old patient was referred during her second pregnancy at 38 weeks of gestation. The referring physician detected a hyperechogenic mass over the vertebra and suspected it to be a spinal lipoma with closed spina bifida. Her medical and obstetric history was unremarkable. Prenatal evaluation was done using a Voluson 730 Pro with a convex volumetric transducer (RAB 4–8 MHz) probe. During her ultrasound evaluation, intracranial findings of spinal dysraphism and vertebral irregularity were absent, and nothing remarkable was observed, except for a left paravertebral hypoechogenic skin mass. The mass was 36x35x18 mm in size. Power Doppler investigation showed high vascularization in the mass (Figure 1). 3D ultrasound, enhanced with power Doppler, permits one to visualize the highly vascular skin lesion (Figure 2). With the aid of 3D ultrasound, the location of the mass was estimated to be between T10-T12 (1) (Figure 3). There was no sign of cardiac failure due to the hypervascular mass. What is your diagnosis?

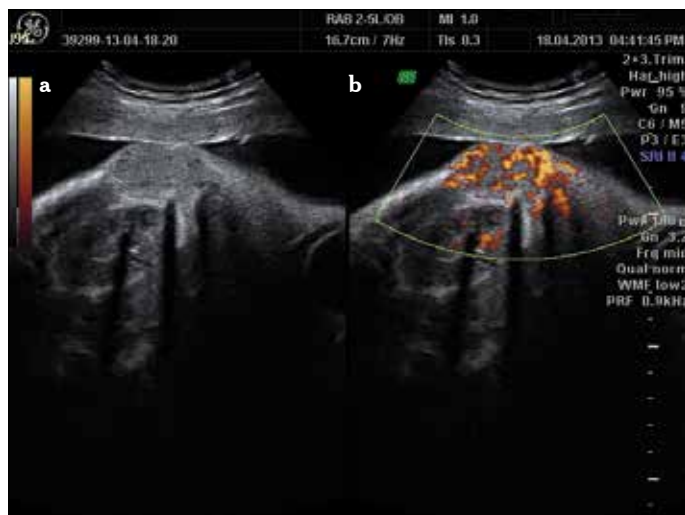


Figure 1. a, b. Prenatal 2D (left) (a) gray scale and (right) (b) power Doppler imaging of the lesion

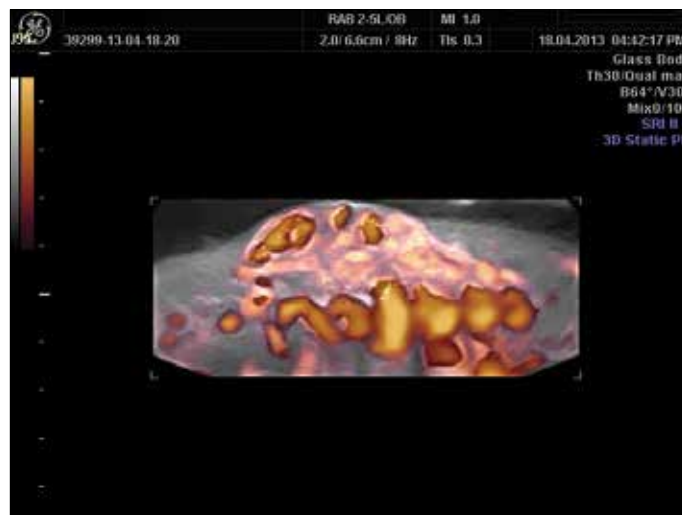


Figure 2. 3D power Doppler angiography of the lesion shows highly vascularized, paravertebral skin mass

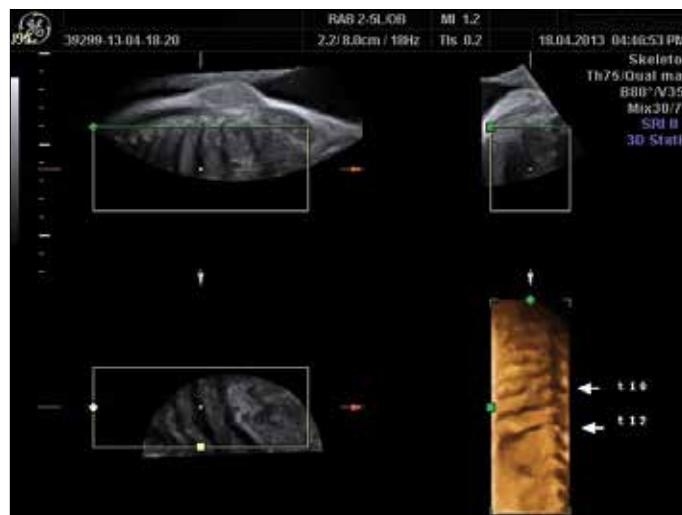


Figure 3. The localization of the mass with 3D ultrasound imaging



Answer

On the same day, she delivered a 3150-g male infant vaginally. He had a 4x3x2 cm skin hemangioma on the left thoracolumbar paravertebral region (Figure 4). The mass was confirmed to be a hemangioma with a postnatal ultrasound evaluation. Fortunately, the newborn had neither thrombocytopenia nor anemia. The newborn was otherwise noted to be healthy. The lesion spontaneously and completely regressed, and no complications occurred during the follow-up period.

Hemangiomas are benign vascular tumors commonly located in the skin and subcutaneous tissue. They are estimated to occur in 0.3% of Caucasian infants (2). Their size is important, because as their size increases, complications, like thrombocytopenia, microangiopathic hemolytic anemia, and Kasabach-Merritt syndrome, may occur (3). Despite these possible important complications, they are rarely diagnosed prenatally. This is probably because during prenatal evaluation, the skin is often omitted.

Major risk factors for the development of hemangiomas are advanced maternal age, placenta previa, preeclampsia, multiple pregnancies, and fair-skinned, female, and premature infants (4). Chorionic villus sampling is also found to increase the incidence of skin hemangiomas (5). Although they are commonly seen alone, they can also be a part of various syndromes, like PHACE syndrome (6). So, careful investigation should also be undertaken for other systems (eg, cardiovascular, facial).

Cutaneous lesions can be located anywhere on the body. Their differential diagnosis should be made, because depending on their location, they can be misdiagnosed as lipoma, fibroma, or even encephalocele. When they are located on the skull, they can easily be confused with an encephalocele. This significantly changes the prognosis and parental counseling. In these cases, visualization of the underlying bone continuity may be used to differentiate.

Fetal cutaneous lesions should also be evaluated with either power or color Doppler in order to determine its vascularization. Highly vascular lesions are mostly hemangiomas, whereas low vascularity suggests masses, like lipomas or fibromas. With the addition of the 3D ultrasound, the localization, size, and volume of the lesion can be determined. These factors are important in counseling the patient about the prognosis of the lesion.

Magnetic resonance imaging (MRI) is another diagnostic method in hemangiomas. However, in most cases, MRI is not needed to establish the diagnosis. MRI can be used, especially for the lesions located on the scalp in order to exclude an encephalocele (7).

When skin hemangiomas are diagnosed prenatally, patients

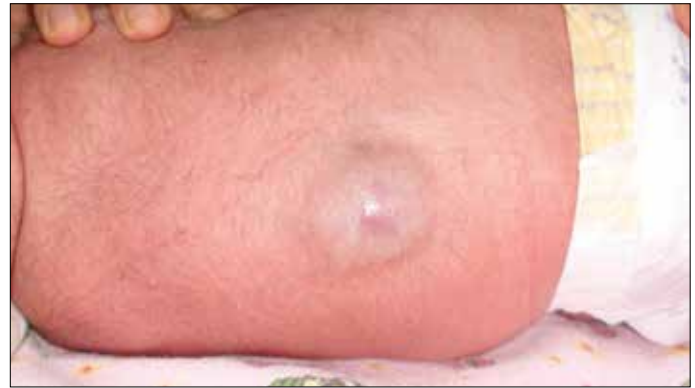

Figure 4. Postnatal photography of the hemangioma

should be counseled that this is a common and spontaneously regressing benign tumor. They can even begin regressing prenatally (8). However, their sizes are important. If large hemangiomas are diagnosed prenatally, the patient should be monitored closely with ultrasound and functional echocardiography. Large hemangiomas can cause thrombocytopenia, anemia, and cardiac failure. So, these patients should be encouraged to deliver in a tertiary health-care facility.

Cihan Çetin, Selim Büyükkurt, Serdar Aykut, Cansun Demir

Department of Obstetrics and Gynecology, Çukurova University Faculty of Medicine, Adana, Turkey

References

1. Buyukkurt S, Binokay F, Seydaoglu G, Kucukgoz Gulec U, Ozgunen FT, Evruke C, Demir C. Prenatal determination the upper level of spina bifida with 3D ultrasound. *Fetal Diagn Ther* 2013; 33: 36-40. [\[CrossRef\]](#)
2. Kanada KN, Merin MR, Munden A, Friedlander SF. A prospective study of cutaneous findings in newborns in the United States: correlation with race, ethnicity, and gestational status using updated classification and nomenclature. *J Pediatr* 2012; 161: 240-5. [\[CrossRef\]](#)
3. Li L, Qin P. Prenatal diagnosis and outcomes of fetuses with cutaneous hemangioma. *Zhonghua Fu Chan Ke Za Zhi* 2006; 41: 605-7.
4. Hemangioma Investigator Group, Haggstrom AN, Drolet BA, Baselga E, Chamlin SL, Garzon MC, et al. Prospective study of infantile hemangiomas: demographic, prenatal, and perinatal characteristics. *J Pediatr* 2007; 150: 291-4. [\[CrossRef\]](#)
5. Bauland CG, Smit JM, Bartelink LR, Zondervan HA, Spauwen PH. Hemangioma in the newborn: increased incidence after chorionic villus sampling. *Prenat Diagn* 2010; 30: 913-7. [\[CrossRef\]](#)
6. Bertelsen T, Salskov-Iversen ML, Stausbøl-Grøn B, Hedelund L. Children with infantile haemangiomas should be worked-up for PHACE syndrome. *Ugeskr Laeger* 2013; 175: 2118-9.
7. Buyukkurt S, Cetin C. Correspondence to the image quiz by Kaymak et al. *J Turk Ger Gynecol Assoc* 2013; 14: 252-3. [\[CrossRef\]](#)
8. Browning JC, Metry DW. Rapidly involuting congenital hemangioma: case report and review of the literature. *Dermatol Online J* 2008; 14: 11.