

## What is your diagnosis?

A 30 year-old female was referred to our hospital with a painless mass of the right inguinal area. The swelling was initially small but gradually increased in size over a period of 10 months. There was no history of trauma, gynaecological problems or previous surgery. On physical examination, a 7x6 cm, rounded, mobile, irreducible swelling was detected superficially in the inguinal area. The volume of this mass increased in standing position, and could be slightly reduced by manual compression. There was no pain on palpation and cough impulse was absent. Sonography was carried out with the patient in prone position. The mass was a

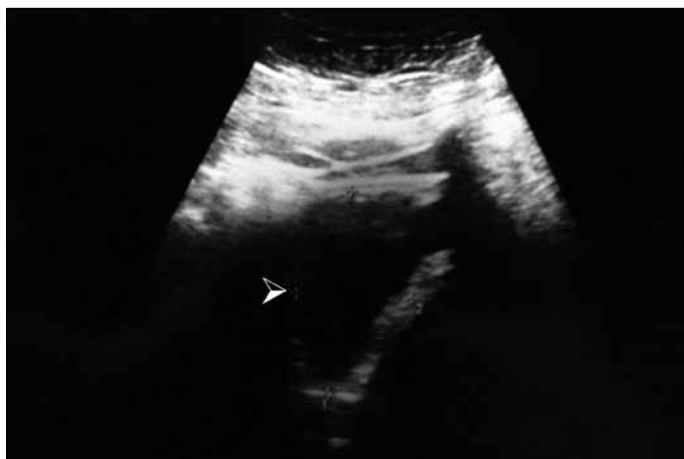

Figure 1. Ultrasonographic appearance of cyst

comma-shaped cyst with a tail directed cranially toward the inguinal canal, measuring 6.4x4.8 cm (Figure 1). There was no vascularity seen in the wall of the cyst on colour Doppler examination. Coronal and axial MR showed a thin walled cystic mass (Figure 2). Considering the clinical symptoms and examination findings, the patient underwent surgical exploration through a lower groin incision. Surgical exploration confirmed the cystic lesion with the patent, fluid-filled canal and the round ligament with a cystic mass was excised (Figure 3). What is your diagnosis?

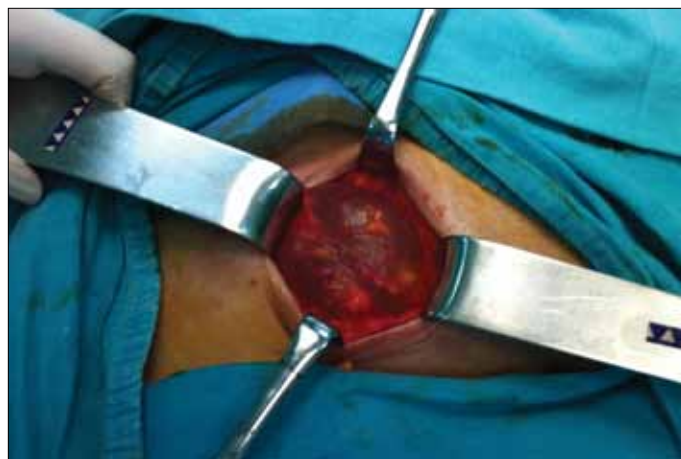

Figure 3. Intraoperative appearance of cyst

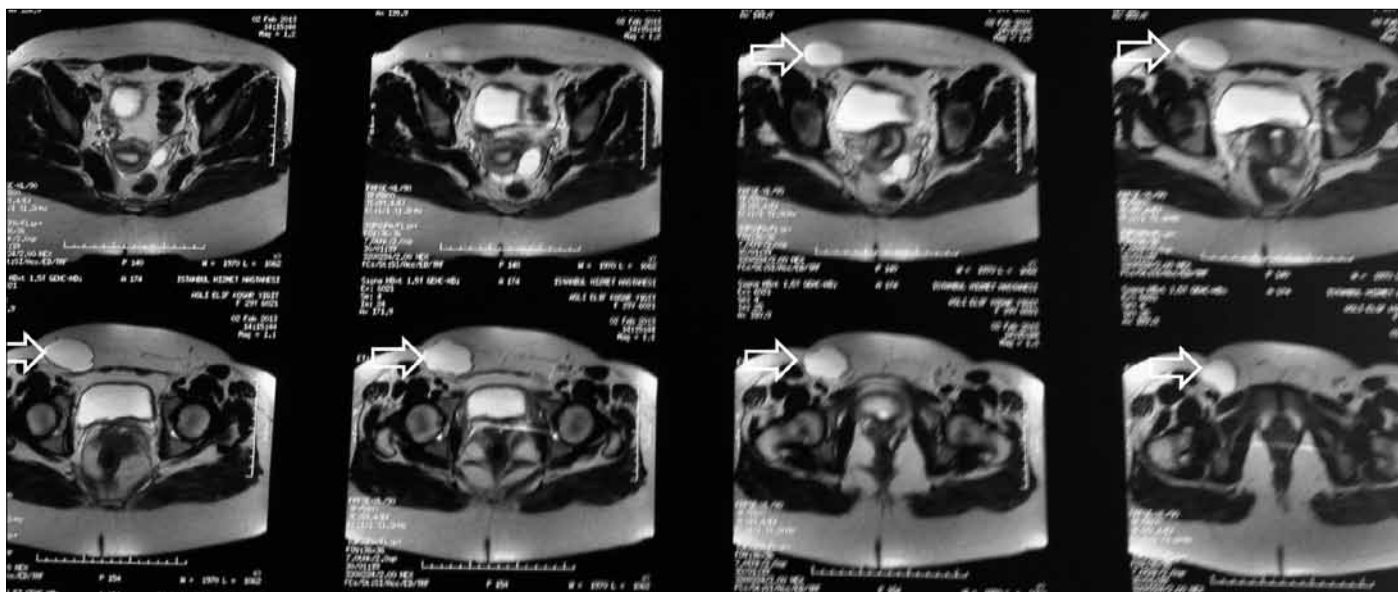


Figure 2. MR appearance of cyst



**Answer**

Pathologic findings were consistent with a hydrocele of the canal of Nuck. In females, evagination of the parietal peritoneum along with the round ligament through the inguinal ring into the inguinal canal forms the canal of Nuck by 6 months of gestation; this is the female counterpart of processus vaginalis in males (1). Complete obliteration of the canal of Nuck usually occurs by the first year of life (2). If obliteration fails in the distal portion of the canal, a sac containing serous fluid remains, which is the so-called hydrocele of canal of Nuck (3). Hydrocele of the canal of Nuck is a rare condition. Clinically, the hydrocele of the canal of Nuck manifests as a painless swelling in the inguinal area and labium majus. The differential diagnosis for inguinal masses in young adult females includes inguinal hernia, lymphadenopathy, Bartholin's cyst and malignant or benign tumours. In this case, diagnosis was clinical and confirmed with ultrasound and MR. Ultrasound is an easy and accurate preoperative diagnostic procedure; a tubular or oval anechoic lesion in the inguinal area or labium majus is observed (4). MR gives a much more precise image and the hydrocele appears as a simple cyst characterised as hypointense on T1-weighted images and hyperintense on T2-weighted images (5).

The treatment choice is surgical excision; the hydrocele in this case was excised through a lower groin incision. In some

cases, laparoscopic closure of a patent canal of Nuck has been reported (6).

In conclusion, the cyst of the canal of Nuck is a rare developmental disorder, but should be taken into consideration in the differential diagnosis of groin tumours in female patients. Ultrasonography and MR are the imaging modalities of choice for evaluating a cyst of the canal of Nuck.

**Cenk Yaşa, Özlem Dural, Ercan Baştu, Aslı Nehir, Samet Topuz**  
Department of Gynecology and Obstetrics, İstanbul Medical School, İstanbul University, İstanbul, Turkey

**References**

1. Anderson CC, Broadie TA, Mackey JE, Kopecky KK. Hydrocele of the canal of Nuck: ultrasound appearance. *Am Surg* 1995; 61: 959-61.
2. Park SJ, Lee HK, Hong HS, Kim HC, Kim DH, Park JS, et al. Hydrocele of the canal of Nuck in a girl: ultrasound and MR appearance. *Br J Radiol* 2004; 77: 243-4. [\[CrossRef\]](#)
3. Schwartz A, Peyser MR. Nuck's hydrocele. *Int Surg* 1975; 60: 91-2.
4. Huang CS, Luo CC, Chao HC, Chu SM, Yu YJ, Yen JB. The presentation of asymptomatic palpable movable mass in female inguinal hernia. *Eur J Pediatr* 2003; 162: 493-5. [\[CrossRef\]](#)
5. Safak AA, Erdogmus B, Yazici B, Gokgoz AT. Hydrocele of the canal of Nuck: sonographic and MRI appearances. *J Clin Ultrasound* 2007; 35: 531-2. [\[CrossRef\]](#)
6. Yen CF, Wang CJ, Lin SL, Chang PC, Lee CL, Soong YK. Laparoscopic closure of patent canal of Nuck for female indirect inguinal hernia. *J Am Assoc Gynecol Laparosc* 2001; 8: 143-6. [\[CrossRef\]](#)

**ADVISORY BOARD OF THIS ISSUE (December 2013)**

Aslı Göker  
Aslı Somunkıran İş  
Belgin Selam  
Bülent Haydardedeoğlu  
Canan Aygün  
Cem Fıçıoğlu

Cemil Yaman  
Deniz Cemgil Ankan  
Ebru Çelik  
Erhan Şimşek  
Güler Şahin  
Jing Liu

Kanchan Mukherjee  
Mehmet Sühha Bostancı  
Mekin Sezik  
Murat Bakacak  
Nafiye Karakaş Yılmaz  
Oktay Kaymak

Servet Özden  
Hacivelioglu  
Tamkin Rabbani  
Yavuz Şimşek  
Yiğit Çakiroğlu  
Yusuf Üstün