

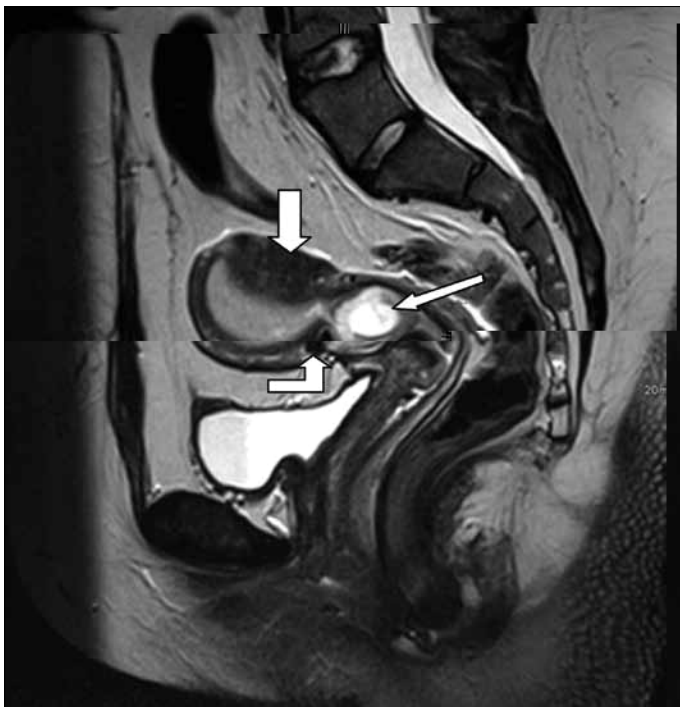
## What is your diagnosis?

---

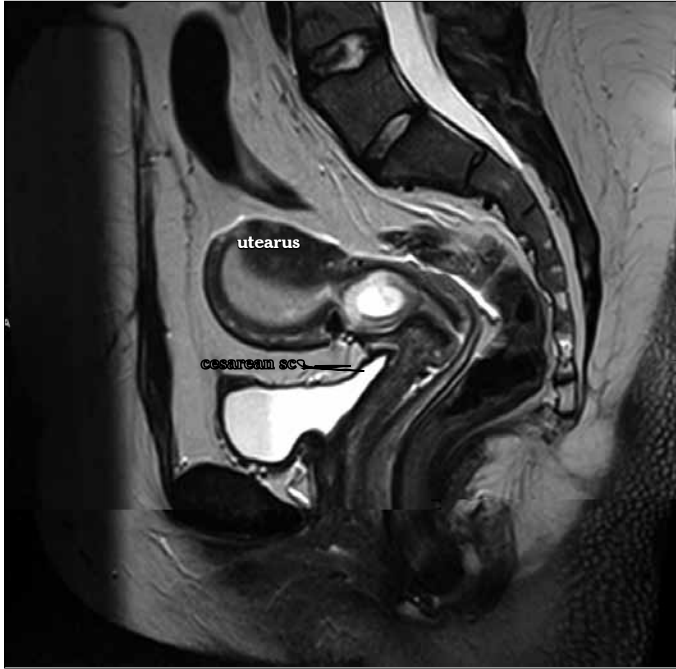A cesarean scar ectopic pregnancy (CSEP) is a pregnancy embedded in the myometrium of a previous cesarean scar, outside the uterine cavity. Its incidence is reported to be as high as from 1 in 1800 to 1 in 2200 (1, 2). A delay in diagnosis and/or treatment can lead to uterine rupture, major hemorrhage secondary to placenta accreta or percreta, a need for hysterectomy and serious maternal morbidity (3-5). Therefore, the main objectives in the management of a cesarean scar ectopic pregnancy should be early and accurate diagnosis and prevention of severe blood loss while preserving fertility.

The diagnosis can be made initially by ultrasonography. However, as presented in this quiz, MRT can be also very useful (Figure 1, 2). Differential diagnosis has to be made with ectopic intramural pregnancy.

There is no consensus about the method of choice for managing CSEP. The use of blind or ultrasound-guided surgical evacuation, medical management with methotrexate (MTX), administered either systemically or locally, and expectant management have all been reported in the literature, as have combined treatments (1-7).



**Figure 1. Please name the structures pointed by the arrows on MRI of the pelvis**



**Figure 2.** MRI imaging of cesarean scar pregnancy

**Cemil Yaman, Richard Mayer**  
Department of Obstetrics and Gynecology,  
General Hospital of Linz, Akh-Linz, Austria

### References

1. Seow KM, Huang LW, Lin YH, Tsai YL, Hwang JL. Cesarean scar pregnancy: issues in management. *Ultrasound Obstet Gynecol* 2004; 23: 247-53. [\[CrossRef\]](#)
2. Jurkovic D, Hillaby K, Woelfer A, Lawrence A, Salim R, Elson CJ. First-trimester diagnosis and management of pregnancies implanted into the lower uterine segment Cesarean section scar. *Ultrasound Obstet Gynecol* 2003; 21: 220-7. [\[CrossRef\]](#)
3. Marcus S, Cheng E, Goff B. Extrauterine pregnancy resulting from early uterine rupture. *Obstet Gynecol* 1999; 94: 804-5. [\[CrossRef\]](#)
4. Chazotte C, Cohen WR. Catastrophic complications of previous cesarean section. *Am J Obstet Gynecol* 1990; 163: 738-42.
5. Rotas MA, Haberman S, Levigur M. Cesarean scar ectopic pregnancies: etiology, diagnosis and management. *Obstet Gynecol* 2006; 107: 1373-7. [\[CrossRef\]](#)
6. Maymon R, Halperin R, Mendlovic S, Schneider D, Herman A. Ectopic pregnancies in a Caesarean scar: review of the medical approach to an iatrogenic complication. *Hum Reprod Update* 2004; 10: 515-23. [\[CrossRef\]](#)
7. Hwu YM, Hsu CY, Yang HY. Conservative treatment of caesarean scar pregnancy with transvaginal needle aspiration of the embryo. *BJOG* 2005; 112: 841-2. [\[CrossRef\]](#)

### ADVISORY BOARD OF THIS ISSUE (March 2012)

A. Akın Sivaslıoğlu  
Arif Serhan Cevrioğlu  
Aysel Derbent  
Bahar Müezzinoğlu  
Banu Bingöl  
Banu Dane  
Başar Tekin  
Batuhan Özmen  
Candan İltemir Duvan  
Cemil Yaman

Ebru Tarım  
Emek Doğer  
Emre Karaşahin  
Eray Çalışkan  
Erhan Şimşek  
Esra Bulgan Kılıçdağ  
Esra Esim Büyükbayrak  
Evrin Erdemoğlu  
Gazi Yıldırım  
Gürkan Kıran

Hasan Cemal Ark  
Kemal Güngördük  
Kemal Naci Kuşçu  
Korhan Kahraman  
Metin İngeç  
Mutlu Meydanlı  
Nur Dokuzeylül  
Önder Çelik  
Tufan Öge  
Yaprak Engin Üstün  
Yiğit Çakıroğlu