

What is your diagnosis?

What is your diagnosis: A woman with a history of cesarean section and chronic cyclic abdominal pain in her history showed these ultrasound findings in the abdominal wall.

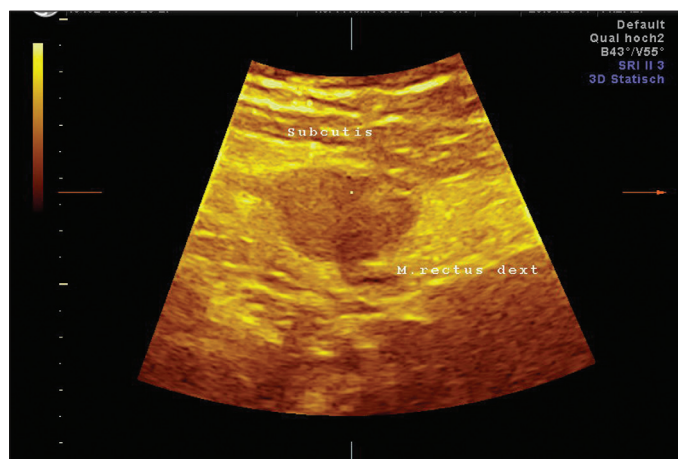


Figure 2. 2D imaging of abdominal wall mass

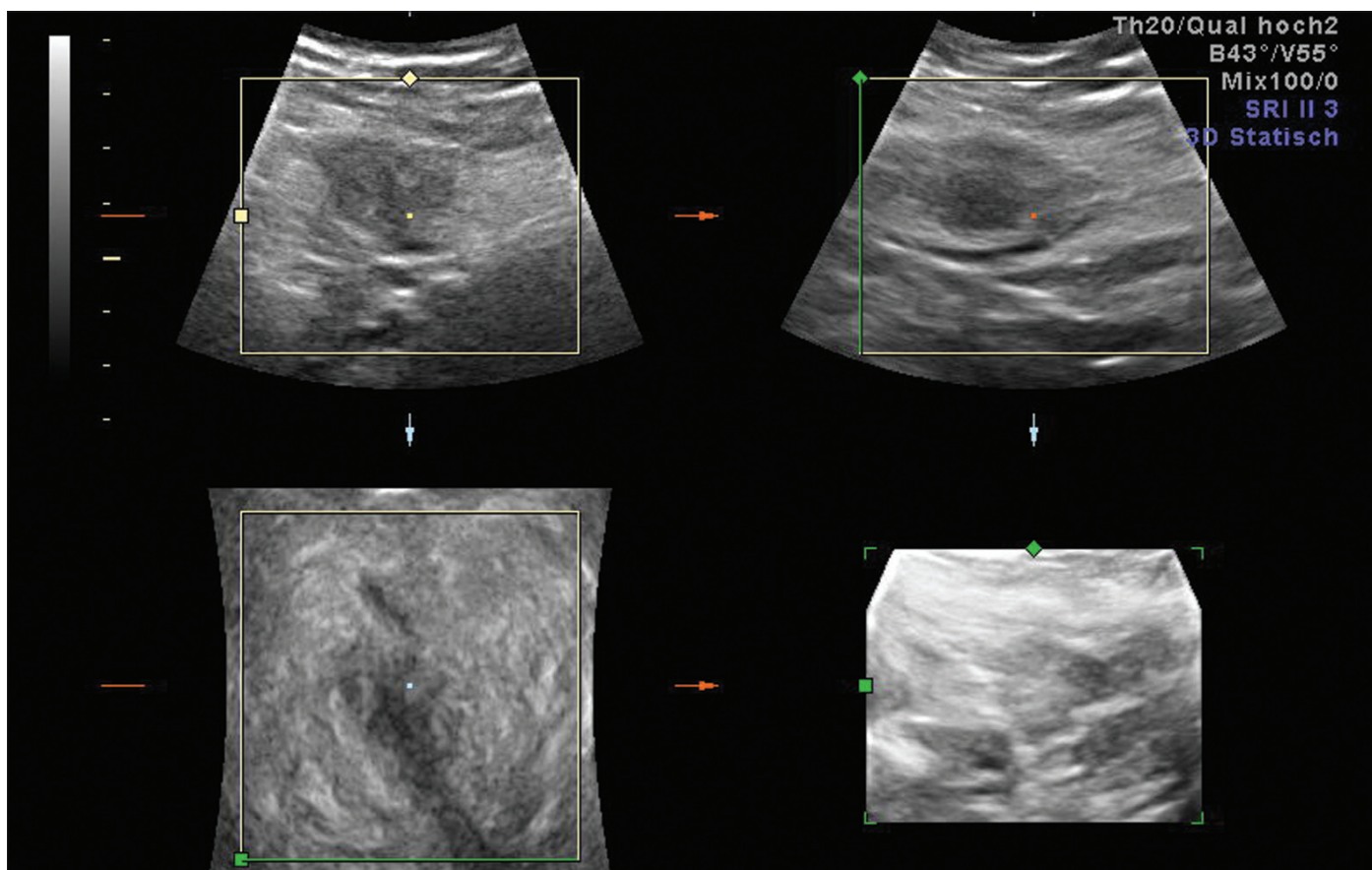


Figure 1. 3D multiplanar imaging of abdominal wall mass

Answer**Abdominal wall endometriosis**

Abdominal wall scar endometriosis is a rare disease which is difficult to diagnose and should always be considered as a differential diagnosis of painful abdominal masses in women (1, 2). Any scar lesion that is involved in response to menstrual cycles should be considered as endometriosis, thus requiring wide surgical resection (1-3). The late onset of symptoms after surgery is the usual cause of misdiagnosis. Furthermore, malignant degeneration of extra pelvic endometriosis is described in the literature (3, 4).

The presented case has a 3x2 cm mass in the abdominal wall as shown with 3D multiplanar view in Figure 1 and with 2D view in Figure 2. The diagnosis is made only after excision and histopathology of the lesion. Preoperative differentials include hernia, lipoma, suture granuloma or abscess. Hence an awareness of the entity avoids delay in diagnosis, helps clinicians to a more tailored treat-

ment and also avoids unnecessary referrals. The definitive diagnosis was established by histopathological studies.

Cemil Yaman, Dietmar Haas, Peter Oppelt
Department of Obstetrics and Gynecology,
General Hospital of Linz, Akh-Linz, Austria

References

1. Singh KK, Lessels AM, Adam DJ, Jordan C, Miles WF, Macintyre IM, et al. Presentation of endometriosis to general surgeons: a 10-year experience. Br J Surg 1995; 82: 1349-51. [CrossRef]
2. Dwivedi AJ, Agrawal SN, Silva YJ. Abdominal wall endometriomas. Dig Dis Sci 2002; 47: 456-61. [CrossRef]
3. Omranipour R, Najafi M. Papillary serous carcinoma arising in abdominal wall endometriosis treated with neoadjuvant chemotherapy and surgery. Fertil Steril 2010; 93: 1347. [CrossRef]
4. Da Ines D, Bourdel N, Charpy C, Montoriol PF, Petitcolin V, Canis M, Garcier JM. Mixed endometrioid and serous carcinoma developing in abdominal wall endometriosis following Cesarean section. Acta Radiol 2011; 52: 587-90. Epub 2011. [CrossRef]

ADVISORY BOARD OF THIS ISSUE (DECEMBER 2011)

Ahmet Gül
Ahmet Yalınkaya
Ali Gedikbaşı
Arif Serhan Cevrioğlu
Aslı Somunkıran
Aysel Derbent
Başak Baksu
Canan Aygün
Cemil Yaman

Ebru Çelik
Eray Çalışkan
Ercan Yılmaz
Erhan Şimşek
Evin Nil Uğurlu
Fulya Kayıkçıoğlu
Gazi Yıldırım
İbrahim Gülhan
Korhan Kahraman

M. Murat Naki
Salih Taşkın
Sefa Kelekci
Selçuk Ayas
Talat Umut Kutlu Dilek
Yalçın Kimya
Yaprak Engin Üstün
Yılmaz Güzel
Yiğit Çakıroğlu