

What is your diagnosis?

A 78-year-old woman living in a nursing home was admitted to our clinic with chronic left-lower quadrant pain. She had to stay in her wheelchair and was not able to walk because of paralysis. She was diagnosed as having Alzheimer's disease. She had no one with her except the nursing home staff. They brought her to the general surgeon because of suspicion of acute appendicitis. After non-conclusive blood tests, a whole abdominal computerized tomography (CT) was performed. The CT revealed a cystic mass with a small notch on the mid pelvis (Figure 1). They referred the patient to our clinic for further evaluation.

She had some debilitating conditions such as hypertension and diabetes as well as Alzheimer. She refused the gynecological examination. On abdominal examination, there was no significant finding but around the patient there was a malodorous smell. The abdominal ultrasound examination showed the same cyst that was seen on CT. The patient was persuaded to undergo a gynecologic exam but, in the supine not the lithotomic position. Inspection of external genitalia were normal. There was bad smelling discharge.

Laboratory parameters including erythrocyte sedimentation rate, complete blood count and blood biochemistry were normal as were tumor markers including CA 125, CA 19-9, carcino embryonic antigen, and α -fetoprotein.

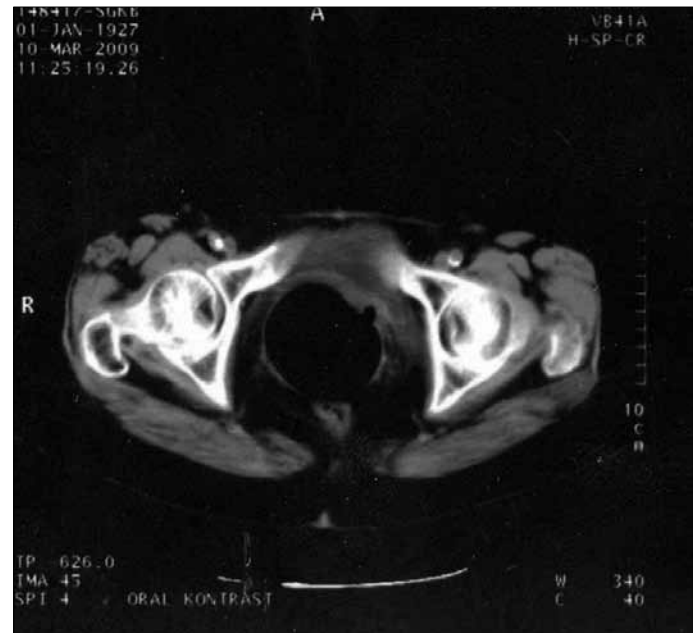


Figure 1. Computerized tomography showed a uniform cyst with a notch on its wall

Answer

Answer Adnexal masses are common among peri- and post-menopausal women. Although ovarian cancer is a significant cause of mortality in menopausal women, large population-based studies demonstrate that the majority of adnexal masses are benign (1). Despite this, the appearance of an adnexal mass is a concern for the patient and an insight exercise for physicians. In most cases, an adnexal enlargement is an incidental finding, generally corresponding to a benign cyst and easily diagnosed by conventional ultrasound. Exceptionally, an ovarian tumour may be malignant and should be treated as early as possible. When conventional ultrasound renders complex morphology, other diagnostic tools must be used such as: colour Doppler and functional tumour vessel properties, serum CA 125 levels, nuclear magnetic resonance imaging and in some cases laparoscopy. Several new tumour markers are being studied for clinical application, although there are presently no clear recommendations. The postmenopausal ovary continues to produce cysts; the prevalence in an ovarian cancer screening population approaches 18%. Yet 60% to 70% of unilocular cysts resolve spontaneously (2). Optimal management of an asymptomatic adnexal mass allows surveillance of women at low malignancy risk while triaging intermediate/high-risk women to surgery. In our case, after convincing the patient to undergo the genital exam in the supine position, digital palpation revealed a balloon in the vagina. The balloon was deflated and removed. It was an inflatable pessary (Figure 2). Probably she forgot about it. The nursing home staff reported that she had spent her last years in

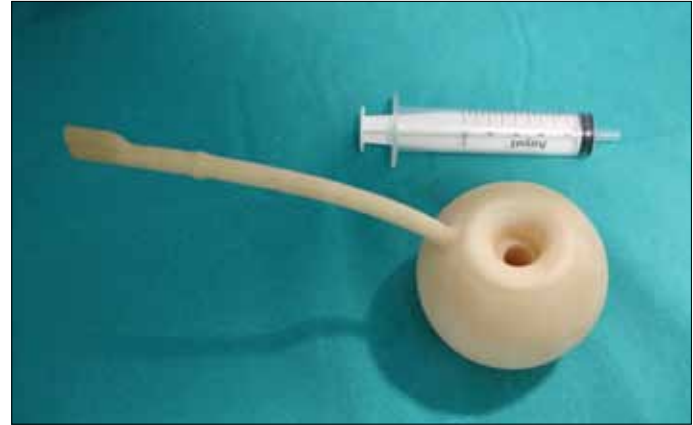

Figure 2. The truth is this cyst is an inflatable pessary

America. We thought that somehow in USA a pessary had been inserted for her pelvic organ prolapsus and after time it was totally forgotten. With this case, the importance of the physical examination and history was revealed once more.

References

1. Pérez-López FR, Chedraui P, Troyano-Luque JM. Peri- and post-menopausal incidental adnexal masses and the risk of sporadic ovarian malignancy: new insights and clinical management. *Gynecol Endocrinol* 2010; 26: 631-43. [CrossRef]
2. McDonald JM, Modesitt SC. The incidental postmenopausal adnexal mass. *Clin Obstet Gynecol* 2006; 49: 506-16. [CrossRef]

ADVISORY BOARD OF THIS ISSUE (SEPTEMBER 2011)

Ahmet Cem İyibozkurt
Ahmet Gul
Ahmet Yalınkaya
Ali Gedikbaşı
Arif Serhan Cevrioglu
Aslıhan Polat
Aylin Pelin Cil
Aysel Derbent
Aysun Karabulut
Bahar Müezzinoğlu
Banu Dane
Banu Kumbak Aygun
Basak Baksu
Basar Tekin
Berna Dilbaz
Canan Aygün
Cem Atabekoglu
Cem Çelik
Cem Fiçicioğlu
Cenk N Sayın
Çetin Yeşilli
Devrim Ertunc Tok

Ebru Tarım
Emek Döğer
Ender Yalçınkaya
Erhan Şimşek
Esra Esim Büyükbayrak
Evin Nil Ugurlu
Evrin Erdemoglu
Faruk Kose
Fulya Kayıkçıoğlu
Gonca Ayşe İmır
Gökhan Yıldırım
Harika Bodur Oztürk
Hori Gazi
Huseyin Gorkemli
Jale Metindir
Kemal Naci Kuşçu
Korhan Kahraman
M. Murat Naki
Mehmet Harma
Mehmet Osmanagaoglu
Mehmet Tunc Canda
Mekin Sezik

Mete Güngör
Murat Ulukus
Narter Celalettin Yeşildağlar
Nur Dokuzeylül
Oya Akcin
Özlem Özdeğirmenci
Özlem Pata
Pelin Coştur Bıyıkız
Petek Balkanlı Kaplan
Rukset Attar
S Sinan Ozalp
Salih Taşkın
Satish Kumar Adiga
Sefa Kelekci
Selçuk Ayas
Serdar Ceylaner
Serdar Filiz
Talat Umut Kutlu Dilek
Tufan Öge
Yalcin Kimya
Yigit Cakiroglu